

CASE REPORT

MAXILLARY ANTROLITH- A RARE CAUSE OF EPISTAXIS

Elangovan S¹, Srinivasa V²

HOW TO CITE THIS ARTICLE:

Elangovan S, Srinivasa V. "Maxillary Antrolith - A Rare Cause of Epistaxis". Journal of Evolution of Medical and Dental Sciences 2014; Vol. 3, Issue 01, January 06; Page: 100-102.

ABSTRACT: Sinoliths are very rare calculi found particularly in maxillary, frontal and ethmoid sinuses. Sinolith present in the maxillary antrum is also called as antrolith. The origin of the nidus of calcification may be extrinsic (foreign body in sinus) or intrinsic (stagnant mucus and fungal ball). Most antroliths are small and asymptomatic. Larger ones may present as sinusitis with symptoms like pain and discharge. An antrolith causing only epistaxis without associated sinusitis is very rare. We report a case of 55 yr. old male who came with h/o epistaxis. On evaluation the CT shows the presence of antrolith in the left maxillary sinus. Caldwell-luc operation was done and the antrolith was removed. We report this case because of its rarity.

KEY WORDS: Sinolith, antrolith, maxillary sinus, epistaxis, Caldwell-luc operation.

INTRODUCTION: Maxillary antrolith is a mineralized mass found very rarely in the maxillary sinus formed by exogenous or endogenous origin.^{1, 2} These mineralized bodies have been variously described as antralrhinoliths, antral calculi, antroliths, sinoliths and antrorhinoliths. They may form around a nidus or concentrated mucus, which continues to grow because of the precipitation of calcium salts in concentric layers.^{1, 2} Small antroliths are usually asymptomatic and may be discovered incidentally on routine radiography of the region.³

CASE REPORT: A 55yr old male presented to us with bleeding from left nasal cavity. The amount of bleeding was around 30 ml and lasted for 10 min. He had three previous episodes for the past 6 months and had treatment from local practitioners. No h/o headache and facial pain, nasal discharge, nasal obstruction and loss of smell. Pt. was a known hypertensive on treatment for the past 7 years. He was not diabetic, not suffering from coronary heart disease and not on any anti-platelet agents. His blood pressure was 130/80. His complete blood examination, liver and renal parameters were normal. On examination there was no swelling over the face and the anterior rhinoscopic examination revealed no active bleeding or blood clots and no mass lesion. Diagnostic nasal endoscopy showed a thin streak of blood coming from left maxillary sinus ostium and tracking towards choana. The nasopharynx was clear. Oral cavity examination showed few missing teeth over upper jaw and lower jaw. CT scan of PNS was ordered to rule out left maxillary sinus tumor. CT scan picture showed features of an antrolith in the left maxillary sinus. (Fig1). Caldwell-luc operation was done and with endoscopic assistance the antrolith was removed. (Fig2&3). Pt. was discharged after a week.

DISCUSSION: Antroliths are calcified bodies within the antral cavity. The term rhinolith was first coined in 1845 to describe a partially or completely encrusted foreign body in the nose¹. The occurrence of true antroliths is very rare, and only a few cases have been reported in the literature up until 2003.^{1, 2} The most commonly involved sinus is the maxillary sinus, followed by the frontal

CASE REPORT

sinus.^{4, 5, 6}The term “maxillary antrolith” was introduced by Bowerman in 1969 to facilitate their classification and description of calculi found within the maxillary sinuses.⁷

The pathogenesis of stone formation within a paranasal sinus is not fully understood. The central core is usually of endogenous and less commonly of exogenous origin. If the central core arises around normal or abnormal body tissues, it is of endogenous origin. These include tooth and bony fragments, blood, pus, mucus, and fungi.^{1, 2, 6} On the other hand, if the nidus for calcification originates outside the body, then it is of exogenous origin.^{1, 2}

Chemical analyses show that these calculi contain various amounts of calcium phosphate, calcium carbonate, calcium oxalate, albuminous material, magnesium phosphate, organic matter and water. The consistency varies from hard and friable to soft, porous, or crumbly. Stones are frequently covered with granulation tissue with a rich blood supply. Color varies from black to gray, brown or white.⁶

Patients with antrolith may be asymptomatic and may be incidentally discovered on routine radiological examination. However, the usual clinical features in symptomatic patients are facial pain, nasal obstruction, epistaxis, purulent or blood-stained discharge, foul smelling postnasal drip and oroantral fistula.^{1, 2, 7} However, dacryocystitis, otorrhoea, anosmia, palatal perforation and septal perforation have been reported in the literature.⁸

The radiographic features of antroliths vary in size, density and outline. Their consistency varies from homogenous or heterogenous density and sometimes shows alternating laminations of radiolucent and radiopaque material. The outline may be rugged or smooth and the shape may be round, oval or irregular. Antroliths must be included in the differential diagnosis of radio-opacities found in or near the maxillary sinus region.^{8, 9}

For epistaxis a range of general causes does not include hypertension per se but rather the underlying problem of atherosclerosis in which changes in the tunica media lead to loss of elasticity and the ability of vessels to constrict. Among the local causes, the infection and inflammation of the mucosa of the nose and para nasal sinuses with/without foreign body or rhinolith/sinolith covered with granulation tissue could cause epistaxis.¹⁰ There was no evidence of sinusitis in our case. In this case antrolith covered with granulation tissue caused the bleeding which was aggravated by the underlying atherosclerosis and hypertension. But for the epistaxis, the antrolith would go undetected.

The management of antrolith should include surgical removal of stone by an endoscopic sinus surgery with or without Caldwell-Luc operation, along with appropriate treatment of the associated condition.

CONCLUSION: Sinolith in the maxillary sinus is still a rare entity and a very rare cause of epistaxis without associated sinusitis. The diagnosis was made by means of nasal endoscopy and CT scanning. The treatment depends on any coexisting sinus disease by FESS surgery to improve sinus drainage. Stone can be removed by an endoscopic approach with Caldwell-luc using either local or general anesthesia.

REFERENCES:

1. Evans J. “Maxillary antrolith: a case report”. British Journal of Oral Surgery 1975; vol. 13; pp: 73–77.

CASE REPORT

- Nass Duce M, Talas DU, Özer C, Yildiz A, Apaydin FD, Özgür A. "Antrolithiasis: a retrospective study". Journal of Laryngology and Otology 2003; vol. 117; pp: 637-640.
- Cohen MA, Packota GV, Steinberg J. "Large asymptomatic antrolith of the maxillary sinus". Oral Surg Oral Med Oral Pathol 1991; vol 71; pp: 155-157.
- Kanzaki S, Sakamoto M. "Sinolith in the ethmoid sinus". J Laryngol Otol 2006; vol 120; p: 11.
- Grant DG, Hussain A, Burge IR. Frontal sinolith. J Laryngol Otol 1998; vol 112; pp: 570-572.
- Ogata Y, Okinaka Y, Takahashi M. "Antrolith associated with aspergillosis of the maxillary sinus: report of a case". J Oral Maxillofac Surg 1997; vol 55; pp: 1339-1341.
- Bowerman JE. "The maxillary antrolith". J Laryngol Otol 1969; vol 83; pp: 873-882.
- Brehmer D, Riemann R. "The rhinolith-a possible differential diagnosis of a unilateral nasal obstruction". Case Reports in Medicine 2010; vol. 2010, Article ID 845671; pp: 1-4.
- Lo SH, Wu YY, Wang PC. "Maxillary Antrolith". Mid Taiwan. J Med 2003; vol 8; pp: 238- 241.
- James B. Snow Jr, John Jacob Ballenger. Ballenger's Otorhinolaryngology Head and Neck Surgery 2003; sixteenth edition; pp: 756-757.

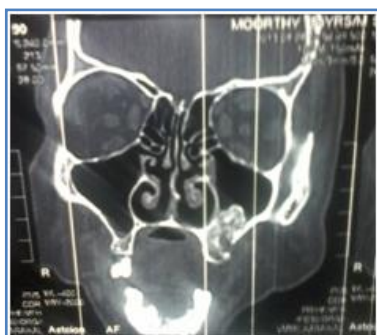

Fig. 1: CT scan showing antrolith

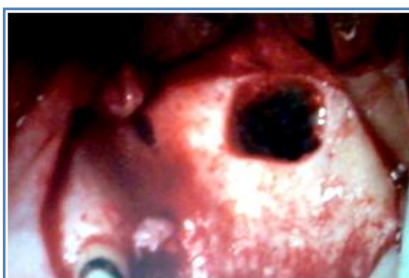

Fig. 2. Caldwell-luc operation image.

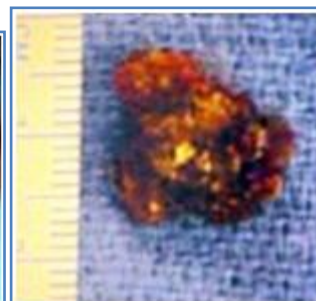


Fig. 3: Antrolith

AUTHORS:

- Elangovan S.
- Srinivasa V.

PARTICULARS OF CONTRIBUTORS:

- Professor, Department of ENT, Vinayaka Mission's Medical College & Hospital, Karaikal, Puducherry-UT.
- Professor and HOD, Department of ENT, Vinayaka Mission's Medical College & Hospital, Karaikal, Puducherry-UT.

NAME ADDRESS EMAIL ID OF THE CORRESPONDING AUTHOR:

Dr. Elangovan S.,
24, Golden Nagar, P.K. Salai,
Karaikal, PIN - 609602,
Puducherry-UT.
Email-hairikshini@yahoo.co.in

Date of Submission: 12/12/2013.
Date of Peer Review: 13/12/2013.
Date of Acceptance: 19/12/2013.
Date of Publishing: 02/01/2014